

Microstomia—A Treatment Challenge to A Prosthodontist

SMRITI KAPUR DEWAN¹, AMAN ARORA², MONIKA SEHGAL³, ANIKA KHULLAR⁴

ABSTRACT

The branch of Prosthodontics is not only a science but also an art of handling patients who present with limitations in continuing with normal procedures. An abnormally small mouth opening is called as microstomia. The common reasons for this condition include scleroderma, orofacial malignancies, surgery, burns and TMJ ankylosis. Impressions can be made for patients with restricted mouth opening with a sectional impression tray that can be assembled and disassembled in the mouth and reassembled outside the mouth. This article describes a sectional tray system for making preliminary and secondary impressions. Also an innovative technique of fabricating a sectional complete denture for a microstomic patient has been described.

Keywords: Rehabilitation, Sectional tray, Sectional denture

CASE REPORT

A 65-years-old edentulous male sought treatment a year back in January 2014, at the Department of Prosthodontics, D.A.V. dental college, Yamuna nagar, Haryana, India, for replacement of his missing teeth. On clinical examination the patient had completely edentulous maxillary and mandibular ridges. The maxillary ridge was favourable and the mandibular ridge was resorbed. The patient was found to have limited mouth opening of about 24 mm [Table/Fig-1]. The patient had a small oral aperture since childhood. The etiology was unknown as there was no history of trauma or TMJ ankylosis. There was no history of smoking, alcoholism or any other systemic disease. The patient refused to undergo surgical enlargement of the mouth aperture. Various treatment options were discussed and the patient accepted the treatment described below. Due to restricted mouth opening of the patient, even the smallest sized available stock tray could not be inserted in the patient's mouth. So we decided to customize the stock trays for primary as well as secondary impression making.

Procedure

Both the maxillary and mandibular stock trays were cut into halves. The line of intersection of the trays was such that it did not compromise the labial frenum. For the stability of the two halves, press button attachments on the tray handles as well as on a steel bar. The trays could be reassembled and stabilized outside mouth with the help of this bar [Table/Fig-2].

A sectional preliminary impression was made by using an irreversible hydrocolloid for one side of the arch. While the material was setting, the other half of the sectional tray was loaded with irreversible hydrocolloid, after which the impression was made. The set impressions were removed sectionally from the oral cavity and reassembled outside by using the press button attachments [Table/Fig-3]. The impression was poured in dental stone to obtain primary cast. Special trays were fabricated on both the casts with auto polymerising acrylic resin. For maxillary special tray, impression tray

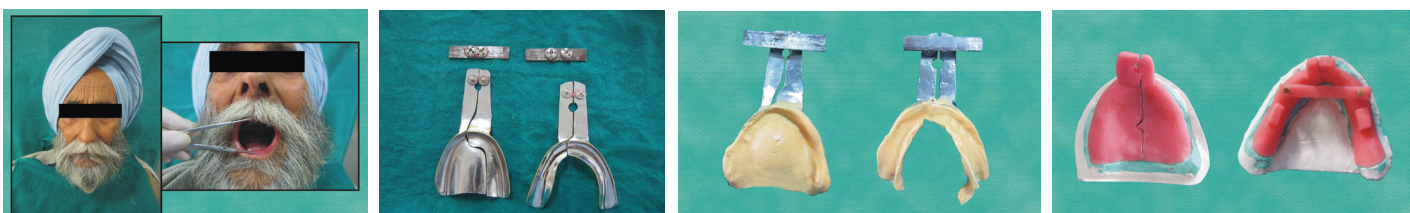
was sectioned into half without compromising the labial frenum and was approximated with the aid of nick and notch both at the palatal region and the handle level [Table/Fig-4].

For mandibular special tray, the special tray was halved and the two parts were stabilised by acrylic bar. Two metal pins, each of 2.5 mm diameter were placed, one on each side of the special tray near the handle. An acrylic resin bar that slid tightly on the pins was prepared [Table/Fig-4]. Border moulding was alternately done for the first and second halves of the sectional trays. Final impression was made by using zinc – oxide eugenol impression paste for maxillary and mandibular arches. After the impression material was set, the right and left halves were removed carefully. The halves were reassembled outside the mouth and were poured by dental stone [Table/Fig-5].

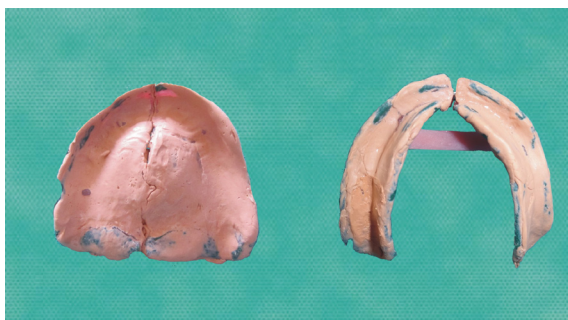
The maxillary and mandibular denture bases were prepared into three and two pieces respectively. Jaw relation was recorded in conventional manner [Table/Fig-6]. Monoplane occlusion was selected and the trial was done. During wax up, two small round magnets were placed in the anterior region of maxillary as well as mandibular denture bases, two press button attachments were placed in the line of intersection of the posterior two halves of the maxillary denture base. The sequential steps of dewaxing, curing, finishing and polishing were done in conventional manner. The complete denture was delivered to the patient and was recalled after 24 hours immediately and a monthly recall was followed for a period of six months. The patient was quite satisfied with the prosthesis [Table/Fig-7].

DISCUSSION

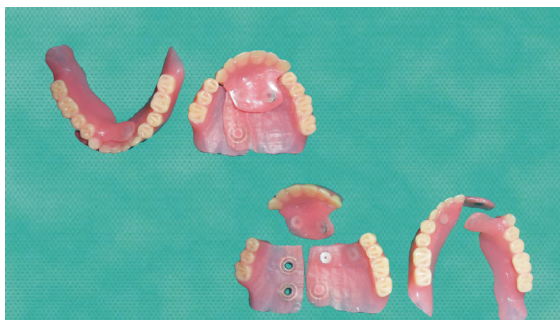Prosthodontic rehabilitation of microstomia patient's present difficulty at all stages from preliminary impression to fabrication of prosthesis [1]. Several management techniques include surgical possibilities such as skin grafts, commissurotomy and local flaps. Non surgical methods include static and dynamic mouth splints, scar massage, exercise programs and modification of denture design [2]. In cases where microstomia is not manageable by surgeries, a modification



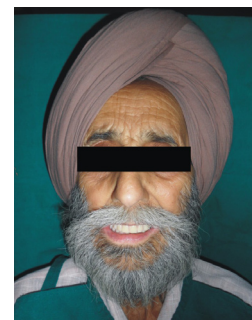[Table/Fig-1]: Pre operative view of the patient [Table/Fig-2]: Sectional stock trays with press button attachments [Table/Fig-3]: Primary impressions [Table/Fig-4]: Custom trays for secondary impression making



[Table/Fig-5]: Secondary impressions



[Table/Fig-6]: Maxillary and mandibular sectional dentures



[Table/Fig-7]: Post operative view of the patient

of the treatment planning and the use of either sectional impression technique and/or sectional complete dentures, can overcome the apparent clinical difficulties [3,4].

The impression stock trays, custom trays, jaw relation recording and fabrication of the denture required technical modifications and special care to treat this particular case. Both the stock trays as well as the special trays have been sectioned for proper recording of the denture bearing area. The attachments used in the tray systems help us to reassemble the trays outside the mouth without any discrepancies. Non anatomic teeth have been selected because the mandibular ridge was resorbed. Magnets have generated great interest within dentistry due to their small dimensions and strong attractive forces allowing them to be placed within prosthesis without being obstructive in mouth. Conventional magnets have been used as retentive devices for removable partial dentures, obturators and maxillofacial prosthesis [5]. In the past various costly or complicated attachment devices e.g. hinge, locking levers, stick lock joints etc. have been used. However, care must be taken to fit the hinge in the midline. Also fitting the hinge higher than the tissue surface had adverse effect of limiting the tongue volume [6,7]. Also, earlier reports have fabricated the maxillary complete denture in two parts which creates the problem of midline diastema as well as problems in phonetics. Here, the maxillary denture had anterior component which had improved esthetics as well as the correct phonetic component present.

Neo magnets have been used for the stability of the prosthesis for this case. In this case, the sectional dentures were stabilized intra orally with small magnets and press button attachments. The attachments were very light in weight and thin but its lab work is tedious. Proper instructions were given to the patient that the prosthesis should not be cleaned in acidic or strong denture cleansing solutions. Mild soap and water could be used without any potential damage to the attachments. Advantages include structural durability, no restriction of tongue space and ease of insertion and removal of the prosthesis. Hence this article presents a customised tray system as well as method of fabrication of sectional maxillary

and mandibular complete dentures which aid in the rehabilitation of a microstomic patient.

CONCLUSION

A non surgical prosthodontic treatment protocol was followed for a patient with microstomia in this particular case. Modifications in the primary and secondary impression procedure were made using customized sectional trays. The sectional custom tray technique is a valuable alternative method of impression making in patients with microstomia, with acceptable accuracy. Furthermore, modified sectional complete dentures helped to overcome the potential clinical difficulties in this case. The maxillary and mandibular sectional dentures were held together with the help of magnets and press button attachments. The procedure was successful in rehabilitation of the microstomic patient, therefore we recommend the same for the management of such cases. However, to determine the long term success, periodic recall, maintenance and further improvements in design are needed.

REFERENCES

- [1] Prithviraj DR, Ramaswamy S, Romesh S. Prosthetic rehabilitation of a patient with microstomia. *Indian J Dent Res.* 2009;20:483-86.
- [2] Aydin Gulses (2011). Microstomia: A Rare but Serious Oral Manifestation of Inherited Disorders, *Advances in the Study of Genetic Disorders*, Dr. Kenji Ikehara (Ed.), ISBN: 978-953-307-305-7, InTech, Available at <http://www.intechopen.com/books/advances-in-the-study-of-genetic-disorders/microstomia-a-rare-but-serious-oral-manifestation-of-inherited-disorders>.
- [3] Givan DA, Auclair WA, Seidenfaden JC, Paiva J. Sectional impressions-a simplified folding complete denture for severe microstomia. *J Prosthodont.* 2010;19:299-302.
- [4] Colvenkar SS. Sectional impression tray and sectional denture for a microstomia patient. *J Prosthodont.* 2010;19:161-65.
- [5] Jajodia M, Palekar U, Choukse V, Sharma R. Magnets in prosthodontics. *NJDSR.* 2014;1(2):82-85.
- [6] Patil V, Limaye M, Shingote S, Mishra K. Prosthodontic rehabilitation of edentulous patient with surgical induced microstomia. *Int J Health Allied Sciences.* 2013;2(4):290-93.
- [7] Kaira LS, Dabral E. Prosthetic management of microstomia with sectional denture. *The Saudi Journal for Dental Research.* 2014;5(2):93-97.

PARTICULARS OF CONTRIBUTORS:

1. Senior Lecturer, Department of Prosthodontics, Sh. J.N. Kapoor D.A.V. Dental College, Yamuna Nagar, Haryana, India.
2. Professor, Department of Prosthodontics, Sh. J.N. Kapoor D.A.V. Dental College, Yamuna Nagar, Haryana, India.
3. Reader, Department of Prosthodontics, Sh. J.N. Kapoor D.A.V. Dental College, Yamuna Nagar, Haryana, India.
4. Post Graduate Student, Department of Prosthodontics, Sh. J.N. Kapoor D.A.V. Dental College, Yamuna Nagar, Haryana, India.

NAME, ADDRESS, E-MAIL ID OF THE CORRESPONDING AUTHOR:

Dr. Smriti Kapur Dewan,
House Number 33, Shakti Nagar, Yamuna Nagar, Haryana-135001, India.
E-mail : doctor_smriti83@yahoo.co.in

FINANCIAL OR OTHER COMPETING INTERESTS: None.

Date of Submission: Dec 12, 2014

Date of Peer Review: Jan 19, 2015

Date of Acceptance: Feb 13, 2015

Date of Publishing: Apr 01, 2015